Current Research in Interdisciplinary Studies, 5(11):1–7, November: 2026.
DOI: https://doi.org/10.58614/cris5111

Current Research in Interdisciplinary Studies
ISSN (Online): 2583-5181

Journal homepage: https://www.jpub.org/journal-details.php?journal-id=40



Research Article

Impact of Alpha-Tocopherol on Azoxystrobin-Induced Histomorphological Changes in the Ovary and Uterus of Female Wistar Rats

Boniface Adakole Onoja [1,2,3*], Adeoye Oyetunji Oyewopo [2], Karimat Oluwadamilola Olowolayemo [2,4], Hikmot Abdulfatai [2] and Amaechi Dennis [5]

[1]*Department of Anatomy, College of Medicine, Federal University of Health Sciences, Otukpo, Benue State, Nigeria.*
[2]*Department of Anatomy, Faculty of Basic Medical Sciences, University of Ilorin, Ilorin, Nigeria.*
[3]*Department of human Anatomy, Veritas University, Abuja, Nigeria.*
[4]*Department of human Anatomy, Al-Hikmah University, Ilorin, Nigeria.*
[5]*Department of Biochemistry, Veritas University, Abuja, Nigeria.*
[*]*Corresponding author: bonnyonoja@yahoo.com*

Article Info

Keywords: *Alpha-tocopherol, Azoxystrobin, Ovary, Uterus, Histomorphology, Oxidative stress, Reproductive hormones, Wistar rats.*

Received: *25.09.2026;*
Accepted: *10.11.2026;*
Published: *24.11.2026*

© 2026 by the author's. The terms and conditions of the Creative Commons Attribution (CC BY) license apply to this open access article.

Abstract

This study investigated the protective effect of alpha-tocopherol against azoxystrobin-induced histomorphological and biochemical alterations in the ovary and uterus of female Wistar rats. Sixteen adult female Wistar rats were randomly allocated into four groups (n = 4 per group): Control (olive oil vehicle, 4 mL/kg body weight), Alpha-tocopherol (150 mg/kg body weight), Azoxystrobin (30 mg/kg body weight), and Azoxystrobin + Alpha-tocopherol (30 mg/kg + 150 mg/kg body weight). All treatments were administered once daily by oral gavage for 28 days. Azoxystrobin exposure significantly reduced serum follicle-stimulating hormone (FSH) levels ($F_{3,12} = 5.044$, $p = 0.017$) and significantly elevated estradiol ($F_{3,12} = 3.825$, $p = 0.038$) and malondialdehyde (MDA) concentrations ($F_{3,12} = 7.629$, $p = 0.004$), indicating endocrine disruption and enhanced lipid peroxidation. Histomorphological examination revealed disruption of normal follicular and endometrial architecture in azoxystrobin-treated animals. Co-administration of alpha-tocopherol attenuated these effects, reducing oxidative stress, improving hormonal balance, and preserving the structural integrity of the ovary and uterus. These findings support a protective, antioxidant-mediated role for alpha-tocopherol against azoxystrobin-induced toxicity in the female reproductive system.

1. Introduction

The rising global demand for agricultural output over the past few decades has driven a corresponding increase in the use of chemical pesticides to improve crop yield and control plant disease. Azoxystrobin, a broad-spectrum strobilurin fungicide, is among the most widely used of these compounds. It acts by inhibiting fungal mitochondrial respiration, specifically blocking electron transfer at complex III of the mitochondrial electron transport chain. Despite its agricultural efficacy, experimental studies have shown that azoxystrobin exposure can also cause reproductive toxicity, metabolic disturbance, and histopathological alteration in non-target mammalian tissues [1, 2].

How To Cite: B. A. Onoja, A. O. Oyewopo, K. O. Olowolayemo, H. Abdulfatai, and A. Dennis. Impact of Alpha-Tocopherol on Azoxystrobin-Induced Histomorphological Changes in the Ovary and Uterus of Female Wistar Rats. *Current Research in Interdisciplinary Studies*, 5(11):1–7, 2026. https://doi.org/10.58614/cris5111

Oxidative stress is one of the principal mechanisms underlying azoxystrobin-induced toxicity. It arises when the production of reactive oxygen species (ROS) overwhelms the body's endogenous antioxidant defences, leading to lipid peroxidation, DNA damage, and disruption of cellular homeostasis, with consequent structural and functional alterations in sensitive tissues such as the ovary and uterus [3]. In female mammals, oxidative stress has been linked to follicular atresia, degeneration of ovarian stroma, and uterine tissue damage. Alpha-tocopherol (vitamin E), a lipid-soluble antioxidant, protects cellular membranes from oxidative damage by scavenging lipid peroxyl radicals and interrupting the chain reaction of lipid peroxidation [4, 5]. Despite this evidence, the literature offers little specific information on the protective role of alpha-tocopherol against azoxystrobin-induced histomorphological changes in the female reproductive system. This study therefore evaluated the impact of alpha-tocopherol on ovarian and uterine tissue following azoxystrobin exposure, with a focus on histomorphological changes and oxidative stress parameters.

2. Materials and Methods

2.1. Experimental Animals and Ethical Approval

Sixteen adult female Wistar rats (100–150 g) were obtained from the Animal Holding Unit of a laboratory in Ogbomosho, Nigeria. The animals were housed under a 12-hour light/dark cycle with free access to standard pellet diet and clean water, and were allowed a two-week acclimatisation period before the commencement of treatment. Ethical approval was obtained from the University of Ilorin Ethics Review Committee (Approval No. DRERC/ASN/ANA/2026/043).

2.2. Chemicals and Reagents

Azoxystrobin was purchased from a chemical warehouse in Ilorin, Nigeria, and alpha-tocopherol was obtained in oil formulation from Prime Health Pharmacy, Ilorin, Nigeria. Both compounds were dissolved or suspended in olive oil, which also served as the vehicle for the control group.

2.3. Experimental Design

Animals were randomly assigned to four groups (n = 4 per group), as summarised in Table 1. All treatments were administered by oral gavage once daily for 28 consecutive days.

Table 1: Experimental design showing group distribution, treatment, and route of administration

Group	n	Treatment	Route & Duration
Group I (Control)	4	Olive oil vehicle, 4 mL/kg BW	Oral gavage, once daily, 28 days
Group II (α-Tocopherol)	4	Alpha-tocopherol, 150 mg/kg BW in olive oil	Oral gavage, once daily, 28 days
Group III (Azoxystrobin)	4	Azoxystrobin, 30 mg/kg BW in olive oil	Oral gavage, once daily, 28 days
Group IV (AZX + α-Toc)	4	Azoxystrobin 30 mg/kg BW + Alpha-tocopherol 150 mg/kg BW	Oral gavage, once daily, 28 days

2.4. Sample Collection and Biochemical Analyses

At the end of the 28-day treatment period, animals were fasted overnight and euthanised by cervical dislocation. Blood was collected by cardiac puncture, and serum was obtained by centrifugation at 2,000 rpm for 15 minutes at 4°C. The ovaries and uterus were excised, weighed, and processed for histological and biochemical analysis. Malondialdehyde (MDA) was quantified by the thiobarbituric acid reactive substances (TBARS) colorimetric method, while superoxide dismutase (SOD) activity and reduced glutathione (GSH) concentration were measured using commercial colorimetric assay kits. Serum concentrations of luteinizing hormone (LH), follicle-stimulating hormone (FSH), progesterone, and estradiol were quantified using sandwich ELISA kits.

2.5. Histological Processing

Ovarian and uterine tissues were processed using the standard paraffin wax embedding technique. Sections were cut and stained with Haematoxylin and Eosin (H&E) for light microscopic examination [6].

2.6. Statistical Analysis

Data were analysed by one-way analysis of variance (ANOVA) followed by Tukey's post-hoc test, using GraphPad Prism version 11.0. Results are expressed as mean $\pm$ standard error of the mean (SEM), and statistical significance was accepted at $p \leq 0.05$.

3. Results

3.1. Effect of Azoxystrobin and Alpha-Tocopherol on Serum Reproductive Hormones

Serum LH and progesterone concentrations did not differ significantly across the four groups. FSH levels, however, were significantly reduced in the Azoxystrobin group relative to Control, and remained significantly lower than Control in the Azoxystrobin + Alpha-tocopherol group

($p < 0.05$), indicating that alpha-tocopherol co-administration did not fully restore FSH levels. Estradiol concentration was significantly elevated in the Azoxystrobin group relative to Control and was significantly higher than in the Azoxystrobin + Alpha-tocopherol group, suggesting that azoxystrobin induced hyperestrogenism that was attenuated by alpha-tocopherol co-administration Table 2, Figure 1.

Table 2: Effect of treatment on serum reproductive hormone levels across experimental groups

Group	LH (mIU/L)	FSH (mIU/L)*	Progesterone (ng/mL)	Estradiol (pg/mL)*
Control	1.3468 ± 0.0076	1.0762 ± 0.0944	0.2375 ± 0.1511	19.606 ± 0.577
Alpha-Tocopherol	1.3247 ± 0.0017	0.8545 ± 0.0440	0.1018 ± 0.0441	22.364 ± 1.439
Azoxystrobin	1.3045 ± 0.0381	0.8225 ± 0.0317[a]	0.1320 ± 0.0077	29.871 ± 4.412[a]
AZX + Alpha-Tocopherol	1.3420 ± 0.0077	0.7923 ± 0.0370[a]	0.1425 ± 0.0291	19.851 ± 1.480[b]

Values are expressed as Mean ± SEM (n = 4). [a] Significantly different from Control ($p < 0.05$). [b] Significantly different from the Azoxystrobin group ($p < 0.05$). * Significant overall ANOVA effect ($p < 0.05$).

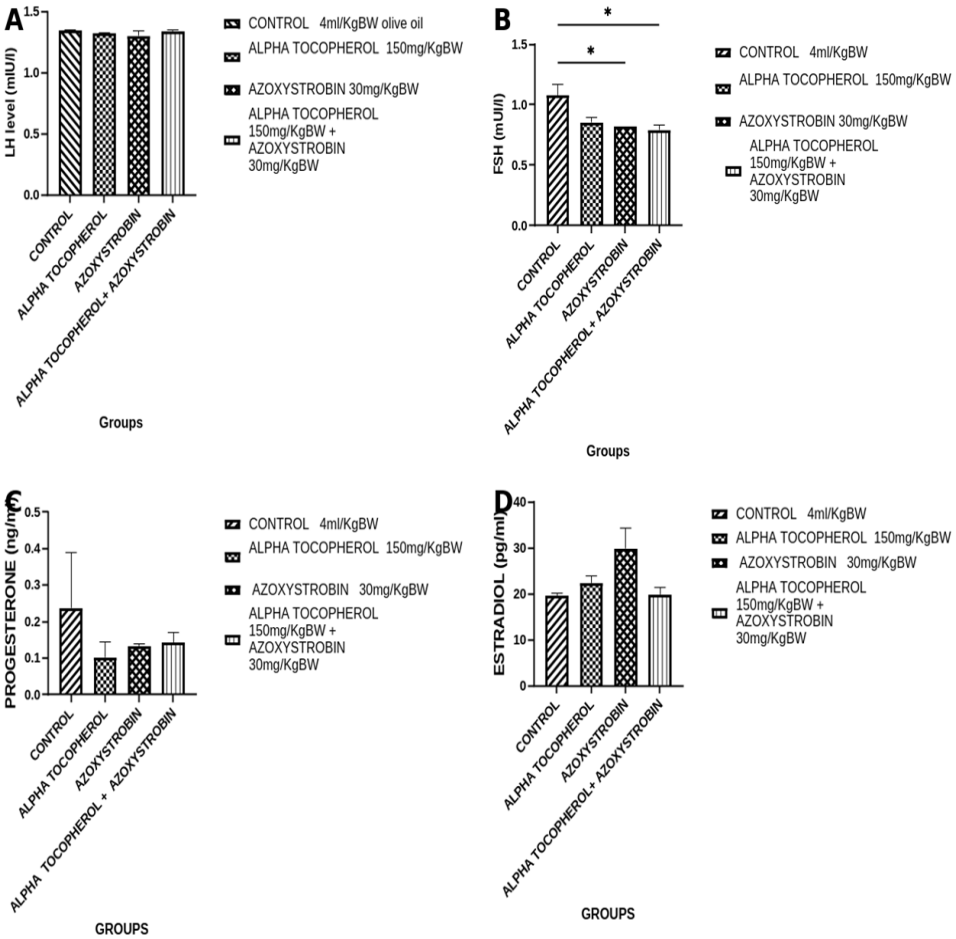

Figure 1: Effect of alpha-tocopherol and azoxystrobin on serum reproductive hormones: (A) luteinizing hormone (LH), (B) follicle-stimulating hormone (FSH), (C) progesterone, and (D) estradiol. Bars represent mean ± SEM (n = 4). *$p < 0.05$ vs. Control (one-way ANOVA, Tukey's post-hoc test)

3.2. Effect of Azoxystrobin and Alpha-Tocopherol on Oxidative Stress Markers

MDA levels were significantly elevated in the Azoxystrobin group compared with both the Control and Alpha-tocopherol groups, confirming azoxystrobin-induced lipid peroxidation. Co-administration of alpha-tocopherol significantly reduced MDA relative to the Azoxystrobin group, although the value remained significantly above Control, indicating partial protection. SOD activity and GSH concentration were numerically, though not significantly, higher in the Azoxystrobin group relative to Control, consistent with a compensatory antioxidant response to increased oxidative burden. In the Azoxystrobin + Alpha-tocopherol group, SOD and GSH values were comparable to Control, suggesting that alpha-tocopherol co-administration reduced the oxidative burden and normalised the antioxidant response Table 3, Figure 2.

Table 3: Effect of treatment on oxidative stress biomarkers across experimental groups

Group	MDA (µM)**	SOD (U/mg protein)	GSH (mM)
Control	1.536 ± 0.344	0.0369 ± 0.0005	0.773 ± 0.264
Alpha-Tocopherol	2.220 ± 0.375	0.0399 ± 0.0063	0.588 ± 0.121
Azoxystrobin	3.720 ± 0.399^{a}	0.0562 ± 0.0166	1.025 ± 0.118
AZX + Alpha-Tocopherol	2.992 ± 0.227^{ab}	0.0396 ± 0.0017	0.764 ± 0.045

Values are expressed as Mean $\pm$ SEM (n = 4). ^{a} Significantly different from Control ($p < 0.05$ or $p < 0.01$). ^{b} Significantly different from the Azoxystrobin group ($p < 0.05$). ** Significant overall ANOVA effect ($p < 0.01$).

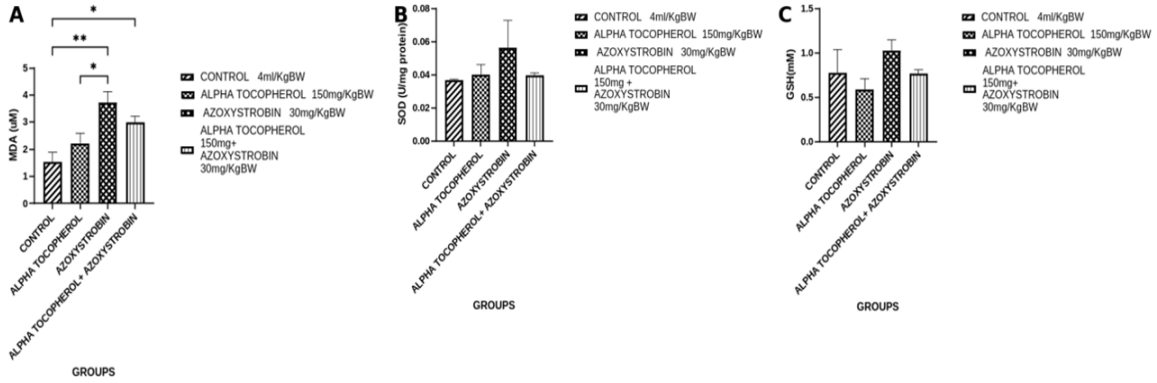

Figure 2: Effect of alpha-tocopherol and azoxystrobin on oxidative stress biomarkers: (A) malondialdehyde (MDA), (B) superoxide dismutase (SOD), and (C) reduced glutathione (GSH). Bars represent mean $\pm$ SEM (n = 4). *$p < 0.05$, **$p < 0.01$ (one-way ANOVA, Tukey's post-hoc test)

3.3. Histomorphological Changes in the Ovary

Ovarian sections from the Control group showed normal follicular development at various stages, with well-defined primordial, antral, and Graafian follicles embedded within compact cortical stroma. The Alpha-tocopherol group similarly showed a preserved follicular population, with identifiable antral and primordial follicles set within well-organised ovarian stroma. The Azoxystrobin-treated group showed alterations in follicular morphology and stromal organisation, consistent with oxidative damage and FSH suppression. The Azoxystrobin + Alpha-tocopherol group showed partial restoration of normal ovarian architecture relative to the Azoxystrobin-only group, with follicular cysts noted alongside identifiable follicular populations and ovarian stroma Figure 3.

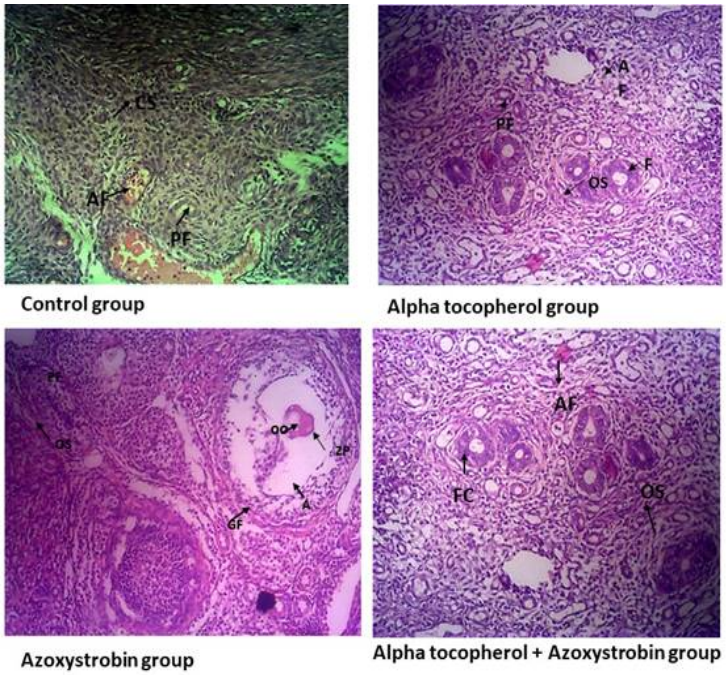

Figure 3: Photomicrographs of ovarian sections (H&E, ×100). Control group showing cortical stroma (CS), antral follicles (AF), and primordial follicles (PF). Alpha-tocopherol group showing antral follicles (AF), primordial follicles (PF), additional follicles (F), and ovarian stroma (OS). Azoxystrobin group showing primordial follicle (PF), ovarian stroma (OS), Graafian follicle (GF) with oocyte (OO), zona pellucida (ZP), and antrum (A). Azoxystrobin + Alpha-tocopherol group showing antral follicles (AF), follicular cysts (FC), and ovarian stroma (OS)

3.4. Histomorphological Changes in the Uterus

The Control group showed an intact endometrium, well-organised endometrial glands, and a well-delineated myometrium with associated blood vessels. The Alpha-tocopherol group showed structurally preserved endometrial stroma, endometrial glands, and myometrium comparable to Control. The Azoxystrobin-treated group showed altered luminal epithelium and glandular morphology, attributable to the hyperestrogenic hormonal environment and direct oxidative membrane damage documented biochemically in this group. The Azoxystrobin + Alpha-tocopherol group showed partial restoration of normal uterine architecture, with identifiable endometrium, myometrium, and blood vessels Figure 4.

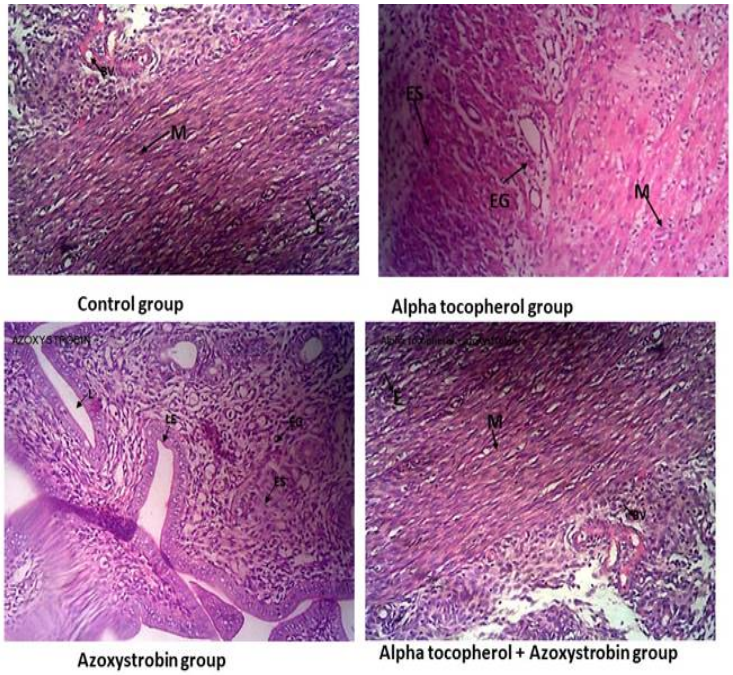

Figure 4: Photomicrographs of uterine sections (H&E, ×100). Control group showing myometrium (M), endometrium (E), and blood vessel (BV). Alpha-tocopherol group showing endometrial stroma (ES), endometrial glands (EG), and myometrium (M). Azoxystrobin group showing lumen (L) lined by luminal epithelium (LE), endometrial glands (EG), and endometrial stroma (ES). Azoxystrobin + Alpha-tocopherol group showing endometrium (E), myometrium (M), and blood vessel (BV)

4. Discussion

The normal growth pattern observed across all groups is consistent with expectations for young adult female Wistar rats maintained on a standard diet. Although body weight was not analysed as a primary endpoint in this study, general observation suggested a somewhat higher relative weight gain in the Azoxystrobin group, which would be consistent with metabolic dysregulation secondary to mitochondrial complex III inhibition [1], and a comparatively lower weight gain in the Azoxystrobin + Alpha-tocopherol group, which may reflect a moderating effect of alpha-tocopherol on this metabolic disruption [5]. Systematic body-weight monitoring would be needed to confirm this observation in future work.

The significant suppression of FSH in the Azoxystrobin group has important implications for ovarian function, given that FSH is the principal driver of follicular recruitment and granulosa cell activity. This suppression is attributable to ROS-mediated impairment of GnRH pulsatility together with the inhibitory feedback effect of elevated estradiol [7]. The markedly elevated serum estradiol in the Azoxystrobin group suggests that azoxystrobin stimulated aromatase activity through oxidative stress mechanisms, resulting in hyperestrogenism, consistent with its established endocrine-disrupting properties [2, 3]. Alpha-tocopherol co-administration restored estradiol to values comparable to Control, most likely by reducing ROS-mediated overstimulation of aromatase activity, supporting its protective role in reversing azoxystrobin-induced endocrine disruption.

The significant elevation of MDA in the Azoxystrobin group confirms azoxystrobin-induced lipid peroxidation as a consequence of mitochondrial ROS generation. The numerically elevated, though non-significant, SOD and GSH values in the same group reflect a compensatory antioxidant response that was ultimately overwhelmed by the oxidative burden [8]. Co-administration of alpha-tocopherol significantly reduced MDA and normalised SOD and GSH, demonstrating its chain-breaking antioxidant action within cellular membranes. The partial but incomplete protection — MDA remained above Control values — suggests that higher doses or combination antioxidant strategies may be needed for fuller amelioration.

The ovarian histomorphological alterations observed in the Azoxystrobin group, including disruption of follicular architecture and stromal organisation, are consistent with the biochemical evidence of significant MDA elevation and FSH suppression in the same group. ROS generated through azoxystrobin's mechanism of action attack granulosa cell membranes and trigger apoptotic cascades within developing follicles, leading to follicular atresia [3, 9]. The partial restoration of ovarian histoarchitecture in the Azoxystrobin + Alpha-tocopherol group is consistent with the significant reduction in MDA and normalisation of estradiol documented biochemically, and is corroborated by studies demonstrating that vitamin E preserves ovarian follicular architecture and reduces connective tissue deposition under pathological oxidative conditions [5, 10].

The uterine histomorphological changes in the Azoxystrobin group are attributable to the hyperestrogenic hormonal environment combined with direct oxidative membrane damage. Sustained elevation of estradiol without adequate progesterone counterbalance is known to drive endometrial hyperplasia and glandular proliferation [11]. The partial restoration of uterine architecture in the Azoxystrobin + Alpha-tocopherol group is consistent with the normalisation of estradiol and significant reduction of lipid peroxidation, and is corroborated by parallel evidence that antioxidant co-administration improves uterine histopathological scores and preserves endometrial glandular architecture in toxicant-exposed rodent models [12].

5. Conclusion

Azoxystrobin induces oxidative stress-mediated reproductive toxicity in female Wistar rats, evidenced by significant elevation of MDA, suppression of FSH, induction of hyperestrogenism, and histomorphological alterations in ovarian and uterine tissue. Co-administration of alpha-tocopherol attenuated these effects through its chain-breaking antioxidant action, reduction of ROS-mediated aromatase upregulation, normalisation of estradiol, and preservation of reproductive tissue structural integrity. These findings support a protective role for alpha-tocopherol against azoxystrobin-induced female reproductive toxicity, with relevance for populations exposed to agricultural fungicides through occupational or dietary routes.

Article Information

Ethical Approval: This study was approved by the University of Ilorin Ethics Review Committee (Approval No. DRERC/ASN/ANA/2026/043), and all procedures involving animals conformed to institutional guidelines for the care and use of laboratory animals.

Informed Consent: Written informed consent was obtained from all participants prior to their enrolment in the study.

Data Availability: The datasets generated and/or analyzed during the current study are available from the corresponding author upon reasonable request.

Conflict of Interest: The authors declare that they have no conflict of interest.

Funding: No external funding was received for this study.

Author Contributions: B.A.O. - Conceptualization, Formal Analysis, Writing – Original Draft; A.O.O. - Conceptualization, Methodology, Supervision; K.O.O. - Data Curation; H.A. - Investigation; A.D. - Resources, Writing – Review & Editing, Project Administration.

Acknowledgments: I hereby acknowledge the guidance of Prof. Ujah, I.O. mni, for his immense fatherly support.

AI Use Disclosure: No generative artificial intelligence tools were used in the preparation of this manuscript.

References

[1] Y. Cao, C. Zhang, B. Li, and J. S. Oh. Azoxystrobin inhibits mitochondrial complex III in non-target mammalian cells. *Toxicology and Applied Pharmacology*, 306:83–92, 2016.

[2] H. N. G. El-Hak, R. A. Al-Eisa, L. Ryad, E. Halawa, and N. S. El-Shenawy. Mechanisms and histopathological impacts of acetamiprid and azoxystrobin in male rats. *Environmental Science and Pollution Research*, 29:43114–43125, 2022. URL https://doi.org/10.1007/s11356-021-18331-3.

[3] W. Gao, C. Zhang, B. Li, and J. S. Oh. Azoxystrobin exposure impairs meiotic maturation by disturbing spindle formation in mouse oocytes. *Frontiers in Cell and Developmental Biology*, 10:1053654, 2022. URL https://doi.org/10.3389/fcell.2022.1053654.

[4] E. Niki. Evidence for beneficial effects of vitamin E. *The Korean Journal of Internal Medicine*, 30(5):571–579, 2015. URL https://doi.org/10.3904/kjim.2015.30.5.571.

[5] Z. Sargazi, M. R. Nikravesh, M. Jalali, H. R. Sadeghnia, and F. Rahimi Anbarkeh. The protective effect of vitamin E on rats' ovarian follicles following an administration of diazinon: An experimental study. *International Journal of Reproductive BioMedicine*, 17(2):105–112, 2019. URL https://doi.org/10.18502/ijrm.v17i2.3985.

[6] A. L. Mescher. *Junqueira's basic histology*. McGraw-Hill, 16th edition, 2021.

[7] G. R. Warner, V. E. Mourikes, A. M. Neff, E. Brehm, and J. A. Flaws. Mechanisms of action of agrochemicals acting as endocrine disrupting chemicals. *Molecular and Cellular Endocrinology*, 502:110680, 2020. URL https://doi.org/10.1016/j.mce.2019.110680.

[8] A. M. Pisoschi and A. Pop. The role of antioxidants in the chemistry of oxidative stress. *European Journal of Medicinal Chemistry*, 97:55–74, 2020.

[9] A. S. H. Alchalabi, N. Ab Rani, E. Aklilu, M. M. Noordin, A. R. Raha, and R. Abdullah. Histopathological changes associated with induced oxidative stress in the ovaries and uterus of female Sprague–Dawley rats. *Asian Pacific Journal of Reproduction*, 5(1):26–35, 2016.

[10] E. G. Bakırhan and S. Kaplan. The protective role of vitamin E against the effects of hyperthyroidism on the rat pituitary–ovary axis. *Histochemistry and Cell Biology*, 163:72, 2025. URL https://doi.org/10.1007/s00418-025-02399-w.

[11] A. E. Elweza, M. A. Marey, I. F. Elesh, M. A. Zinnah, I. Akthar, C. Kanno, M. Takagi, and A. Miyamoto. Zearalenone interferes with the sperm-triggered inflammation in the bovine uterus in vitro: Negative impact on sperm motility and survival. *Reproductive Toxicology*, 107:81–89, 2022. URL https://doi.org/10.1016/j.reprotox.2021.12.001.

[12] F. Uysal, G. Sukur, N. Bozdemir, and O. Cinar. Antioxidant supplementation may effect DNA methylation patterns, apoptosis, and ROS levels in developing mouse embryos. *Histochemistry and Cell Biology*, 162:347–359, 2024. URL https://doi.org/10.1007/s00418-024-02286-w.